

CASE REPORT

Open Access



14-month-old female with anti-MDA5 juvenile dermatomyositis complicated by liver disease: a case report

Mitchell Kinkor¹, Sameena Hameed², Alexander Kats³, Voytek Slowik⁴, Emily Fox⁵ and Maria Ibarra^{5*}

Abstract

Background Juvenile Dermatomyositis (JDM) is a rare disorder with subtypes associated with different myositis-specific antibodies (MSAs) including anti-MDA5. Hepatic involvement in JDM is rare and has not previously been documented in anti-MDA5 JDM. There is a lack of formal research on treatment protocols for anti-MDA5 JDM, though tofacitinib is a highly regarded emerging therapy.

Case presentation A previously healthy 14-month-old Hispanic female presented to a pediatric rheumatology clinic with eight months of worsening rash, weakness, periorbital edema, intermittent fevers, and weight loss. Her physical exam was notable for fever, thinning of hair, heliotrope rash, periorbital edema, violaceous macules on her bilateral elbows, forearms, arms, and knees, arthritis, Gottron's sign, and hepatomegaly. The patient was admitted, and symptoms progressed to include hypoxemia. Subsequent workup was notable for ground glass opacities of bilateral lung fields on chest CT, myositis visualized on MRI and confirmed with muscle biopsy, and liver biopsy showing nonspecific signs of liver injury. After a thorough infectious disease workup to rule out concomitant infection, the patient was started on high-dose steroids and induction with cyclophosphamide. She responded well with disease remission maintained with tofacitinib in the outpatient setting.

Discussion and conclusions Our patient is notable due to her young age at presentation, histopathologically confirmed liver injury, and response to treatment. The case adds to the growing body of literature supporting tofacitinib for anti-MDA5 JDM in the pediatric population. Future research can better standardize effective treatment protocols and define the mechanism of liver involvement. For patients with nonspecific liver injury, muscular, and cutaneous disease, anti-MDA5 JDM should be considered in the differential diagnosis with treatment options including tofacitinib for confirmed cases.

Keywords Juvenile dermatomyositis, Anti-MDA5, Fever, Tofacitinib, Ductopenia

*Correspondence:

Maria Ibarra

mibarra@cmh.edu

Full list of author information is available at the end of the article



© The Author(s) 2024. **Open Access** This article is licensed under a Creative Commons Attribution-NonCommercial-NoDerivatives 4.0 International License, which permits any non-commercial use, sharing, distribution and reproduction in any medium or format, as long as you give appropriate credit to the original author(s) and the source, provide a link to the Creative Commons licence, and indicate if you modified the licensed material. You do not have permission under this licence to share adapted material derived from this article or parts of it. The images or other third party material in this article are included in the article's Creative Commons licence, unless indicated otherwise in a credit line to the material. If material is not included in the article's Creative Commons licence and your intended use is not permitted by statutory regulation or exceeds the permitted use, you will need to obtain permission directly from the copyright holder. To view a copy of this licence, visit <http://creativecommons.org/licenses/by-nc-nd/4.0/>.

Background/Introduction

Juvenile dermatomyositis (JDM) is a rare systemic inflammatory disorder that is characterized by inflammatory infiltration of striated muscle and skin, along with vasculopathy and arthropathy [1]. JDM vasculopathy principally affects muscles and skin but may affect other organs and cause constitutional symptoms. The etiology of JDM is not completely understood, though the HLA-DR3 marker is strongly associated, and certain myositis-specific antibodies (MSAs) have given potential clues into the pathophysiology of the disease [1, 2]. Anti-MDA5 is a MSA that has been associated with a distinct clinical phenotype—cutaneous and oral ulceration along with arthritis in the majority of patients, with approximately 20% of patients also developing interstitial lung disease as part of their clinical course [3–5]. There is a paucity of literature describing liver disease in JDM, with only rare implication of liver disease in the adult population [6, 7]. The median age of disease onset with anti-MDA5 associated JDM is six years [2]. Patients under the age of three years were significantly more likely to be female, have a preceding fever, and have a family history of autoimmune disease. Patients under three were less likely to have symptoms classically described in the older population including a heliotrope rash, Gottron's sign, capillary loop abnormalities, and elevations in creatine kinase, aspartate aminotransferase, or aldolase [8, 9].

Currently, early aggressive treatment with high-dose oral and IV steroids in combination with methotrexate and IVIG are the cornerstones of management of JDM [1]. Rituximab, cyclophosphamide, and tofacitinib can also assist in treatment of anti-MDA5 JDM [10, 11]. Tofacitinib has recently emerged as a promising therapy as its JAK inhibition has been shown to reduce interferon-induced STAT1 phosphorylation that has been shown to be associated with impaired muscle repair seen in dermatomyositis [11]. Here we detail the case of a 14-month-old girl who presented with many of the typical clinical features of anti-MDA5 JDM including cutaneous, joint, muscle, and pulmonary disease, however she also presented with atypical features of liver disease and cyclic fevers that complicated her treatment course.

Case presentation

A previously healthy 14-month-old Hispanic female presented with eight months of worsening rash, weakness, periorbital edema, intermittent fevers, and weight loss. Symptoms started with cough, congestion, and fever at approximately six months of age. She was treated by her primary care provider (PCP) with a five-day course of prednisolone. After completing the course of steroids, she developed a rash on her left arm. The rash persisted despite treatment with moisturizers. The patient then

received her one-year-old vaccines (six months following her initial presentation) with subsequent spreading of her rash. Her rash was described as “bruise-like” and spread to include all four extremities along with truncal involvement. Her activity level declined, and she appeared weaker to family members. Six weeks after vaccines (and two weeks prior to presentation for admission to hospital) she began to have daily fevers. She was evaluated again by her PCP four days prior to hospital presentation with lab work obtained showing elevated transaminases, creatine kinase (CK), alkaline phosphatase, gamma-glutamyl transpeptidase (GGT), lactate dehydrogenase (LDH) and a positive antinuclear antibody and ribonucleoprotein antibody. She was subsequently referred to pediatric rheumatology for urgent evaluation.

On the day of presentation to the rheumatology clinic, the patient was noted to be thin with her weight in the fifth percentile at 7.9 kg. Her exam was notable for thinning of hair, heliotrope rash, periorbital edema, and violaceous macules on her bilateral elbows, forearms, arms, and knees (Fig. 1). Many of the violaceous macules were also ulcerative, progressing throughout admission. The upper extremity exam was notable for bilateral and symmetric Gottron's sign and nail fold erythema (Fig. 2). She also had arthritis along with an ulcerative lesion on her left ankle (Fig. 3). The abdominal exam was notable for hepatosplenomegaly. Nail fold capillaroscopy was moderately abnormal. The patient was admitted to expedite her work up with a broad differential including juvenile dermatomyositis, an overlap syndrome, and autoinflammatory syndromes.

Pertinent positive initial lab work included a respiratory viral panel positive for parainfluenza, elevated transaminases (with normal INR) CK, LDH, aldolase, and bilirubin. A myositis antibody panel including anti-MDA5 was drawn on admission as well. Genetics was consulted and targeted exome sequencing was ordered due to suspicion for syndromic disease based on a broad forehead, triangular facies, protruding ears, smooth philtrum, and thin upper lip.

Initial imaging was notable for mild right ventricular hypertrophy on echocardiogram with previously undiagnosed atrial septal defect, gallbladder sludge, and liver span of 10 cm (upper limit of normal) on abdominal ultrasound, bilateral hip, and thigh myositis with inguinal lymphadenopathy on MRI pelvis, and patchy areas of consolidation and ground glass opacities of bilateral lower lobes on CT chest.

Following the initial diagnostic workup, the patient continued to fever daily for the first ten days of admission. Her rash evolved to include ulceration of bilateral knees, elbows, and metacarpals. While her respiratory status was initially stable, supplemental oxygen was needed

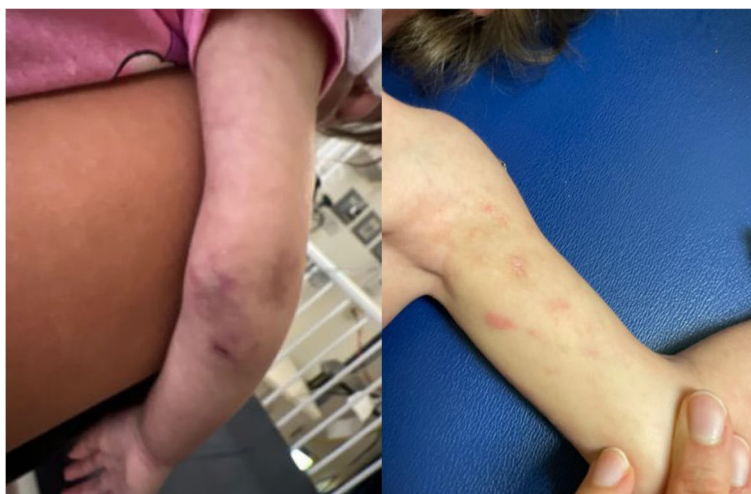

Fig. 1 Ulcerative violaceous macules of R elbow, L arm

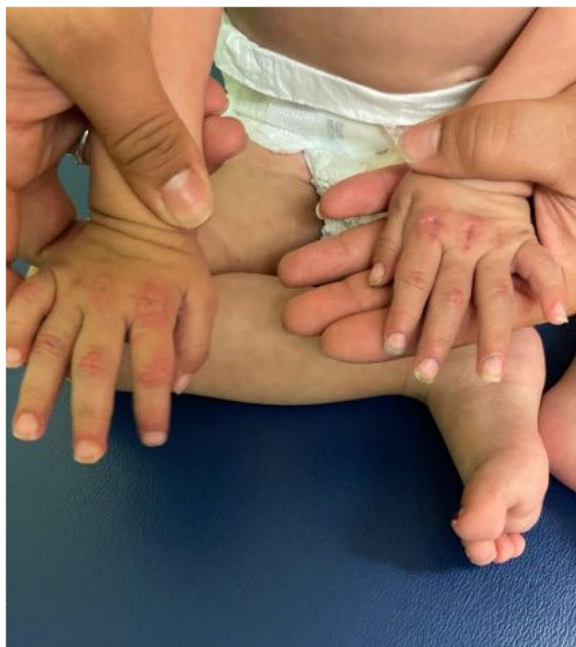

Fig. 2 Symmetric ulcerative Gottron's sign and nail fold erythema

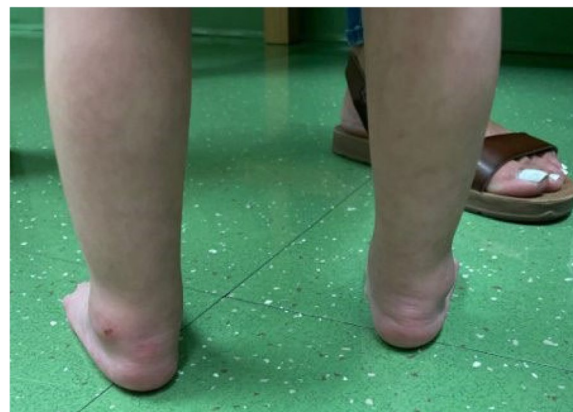

Fig. 3 Ulcerative lesion of L ankle

due to hypoxia on hospital day three and she continued to have an oxygen requirement throughout the hospital course.

Though findings of the MRI pelvis and CT chest were suggestive of dermatomyositis, immunosuppressive treatment was not immediately initiated due to the need to rule out infectious causes in the setting of two weeks of fever. Further infectious workup was negative over the coming days including testing for Histoplasma, HIV, EBV, viral hepatitis, and tuberculosis.

Additionally, muscle and liver biopsies were obtained on hospital day five. On hospital day eight, a liver biopsy resulted positive for nonspecific mixed inflammatory infiltrate (Fig. 4a-c) and areas of ductopenia and ductular proliferation (Fig. 4d). The patient was also treated with a five-day course of vancomycin and cefepime for hospital acquired pneumonia starting on hospital day eight, but fever curve and oxygen requirement were unchanged over the following three days.

On hospital day 11, preliminary results of the muscle biopsy were positive for dermatomyositis with MHC staining pending. Methylprednisolone was initiated at 30 mg/kg daily for three days. The patient responded well, particularly her cutaneous features, strength, and overall energy, though oxygen requirement persisted. IVIG 2 g/kg was given on hospital day 14 and steroid dosing was switched to 2 mg/kg/day. On hospital day

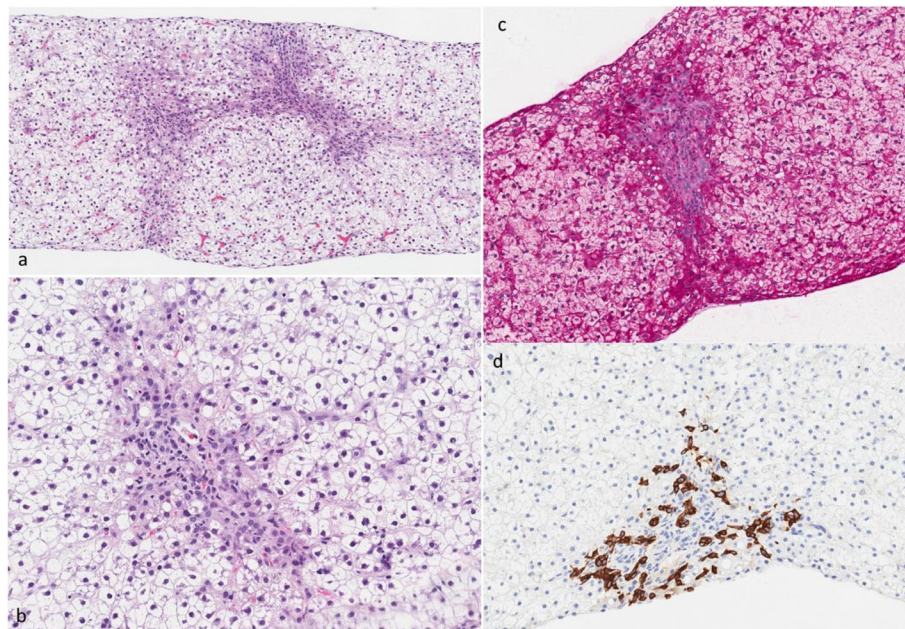


Fig. 4 a-d. Liver histopathology, **a** Liver core, (H&E 100X). The liver core demonstrates hepatocellular damage with feathering and ballooning of hepatocytes in the lobules. **b** Liver core, (H&E 200X). The portal area demonstrates mild portal inflammation including eosinophils and rare neutrophils, ductular proliferation, and ductopenia. **c** Liver core, (PAS 200X). Significant glycogen depletion in the hepatocytes. **d** Liver core, (CK-7 200X). Cytokeratin-7 immunohistochemical stain showing prominent ductular proliferation at the periphery of the portal area, and absence of the central duct (ductopenia)

16, anti-MDA5 antibody results returned positive. After IVIG treatment, cyclophosphamide was initiated at 500 mg/m² on hospital day 19. The patient’s clinical status gradually improved over the next two weeks, and she was discharged on room air though she did require honey thickened formula feeds at home due to video fluoroscopic swallow study showing signs of aspiration near time of discharge while transitioning from nasogastric to oral feeding. Liver function tests

gradually returned to normal over time without evidence of chronic liver disease (Table 1).

Of note, her genetic evaluation did not reveal any syndromic pathology specific to the patient’s presentation but did return positive for three variants of unknown significance (ERBIN, RFT1, RRM2B) along with known pathogenic variant TMEM67 – causative for ciliopathies but thought to be non-contributory to patient’s initial presentation. Final muscle biopsy results were consistent

Table 1 Liver function tests throughout hospitalization (normal range in parentheses)

Hospital Day	AST (20–77 u/L)	ALT (less than 44 u/L)	GGT (10–78 u/L)	Indirect Bilirubin (0.0–1.2 mg/dL)	Direct Bilirubin (0.0–0.4 mg/dL)	Albumin (2.9–5.1 g/dL)
1	702 H	155 H	233 H	0.3	1.5 H	3.3
5	428 H	86 H	187 H	0.2	1.1 H	2.1 L
8	765 H	110 H	293 H	0.3	1.3 H	3.1
10 (high dose methylprednisolone initiated day 11)	1,577 H	204 H	564 H	0.2	1.5 H	3.0
13 (IVIG initiated day 14)	1,365 H	207 H		0.2	1.1 H	3.4
19 (cyclophosphamide initiated day 19)	911 H	273 H		0.3	0.6 H	3.7
25	359 H	249 H	608 H	0.2	0.5 H	4.0
32	158 H	108 H	329 H	0.3	0.4	3.8
34 (day of discharge)	86 H	83 H		0.1	0.3	3.9
2-week post discharge follow up	47	27	77	0.4	0.1	4.4

with dermatomyositis as well as features of congenital LMNA myositis seen in various congenital muscular dystrophies though genetic analysis in our patient did not show any LMNA mutations.

After induction with six months of cyclophosphamide, IVIG infusions, and decreasing frequency of methylprednisolone pulses, our patient was started on maintenance tofacitinib in the outpatient setting. JAK inhibitor therapy with tofacitinib was selected based on the patient's significant ulcerative skin disease, the presence of anti-MDA5, and recent reports of patients being recalcitrant to standard therapy [11]. Her initial dose started at 3.2 mg twice daily but one month into treatment after facial rash was observed and tofacitinib dose was increased to 5 mg twice daily to sustain remission of skin and muscle disease. In the 12 months since the dose was increased, our patient has not experienced any flares of disease.

Discussion and conclusions

JDM patients (including anti-MDA5 JDM) typically present around six years of age, and previous literature has suggested that anti-MDA5 JDM patients may have a bimodal presentation around three years of age and six years of age. Phenotypically, those who present younger are more likely to have febrile presentation without significant cutaneous involvement [4, 8]. At 14 months of age with significant cutaneous and muscular involvement of disease our patient is an outlier even within the population of anti-MDA5 JDM patients. Her aspiration risk secondary to weakness complicated her recovery course, a risk likely not present in patients of older age.

The patient's liver involvement was an additional complicating factor in our management of her case. Hepatic pathology is difficult to detect in dermatomyositis as AST/ALT and CK can be elevated due to muscular injury without hepatic involvement. Along with hepatomegaly on the exam, this patient had hyperbilirubinemia, elevated GGT, and hypoalbuminemia consistent with liver disease.

The incidence of hepatic involvement in JDM is very rare (only one pediatric case report found in our literature review – a 14-year-old male), and poorly defined specific to anti-MDA5 disease [6]. A retrospective cohort study showed that 20% of adult dermatomyositis patients had some degree of liver dysfunction, with liver involvement correlating with the presence of anti-MDA5 antibodies [7]. Four adult patients with anti-MDA5 DM and liver involvement were biopsied, and signs of non-specific liver damage were observed including steatosis, hepatocyte ballooning, and glycogenated nuclei. Our patient's biopsy showed non-specific liver inflammation as well (Fig. 4a-c), and it did have ductal involvement not

previously described in liver biopsy results from adult or pediatric patients with dermatomyositis (Fig. 4d) [6, 7].

Further, before initiating high-dose steroids, a thorough infectious disease workup was completed due to a history of two weeks of fever. Additionally, treatment for hospital-acquired pneumonia was started on day eight of admission. Even though fever at presentation has been documented in most patients under three years old, infectious workup that delayed treatment was necessary due to the high risk of harm if a concomitant infectious process was present during high-dose steroid treatment [8]. Although the patient's course was complicated, she responded well to initial treatment with high-dose steroids, IVIG, and cyclophosphamide followed by maintenance tofacitinib and low-dose steroids in the outpatient setting. Methotrexate was avoided due to concern for further liver injury. First and second-line standard treatment has been used for anti-MDA5 JDM along with other biologic therapies such as abatacept, though tofacitinib use has increased in frequency with recent case reports documenting its efficacy in pediatric patients with anti-MDA5 JDM [11].

Our patient's symptoms worsened shortly after one-year vaccinations. Recently, an association between COVID-19 vaccination or infection and dermatomyositis has been described, however, our patient did not have a documented COVID-19 infection and was not vaccinated for COVID-19 [12]. There is also an association between the Hepatitis B vaccine and dermatomyositis though the dose our patient received at her one-year vaccinations would have been her fourth dose with no difficulty or intolerance of prior 3 doses, making vaccine induced etiologies less likely [13].

Our patient is notable due to her young age at presentation, histopathologically confirmed liver injury, and documented response to tofacitinib. Cases of anti-MDA5 JDM with liver involvement and lung involvement may be fatal, but our patient achieved a good outcome following aggressive treatment and tofacitinib initiation. The case adds to the growing body of literature supporting tofacitinib for anti-MDA5 JDM in the pediatric population [11]. Future research can better standardize effective treatment protocols and better describe the incidence of liver involvement in the JDM population. For patients with nonspecific liver injury, muscular, and cutaneous disease, anti-MDA5 JDM should be considered in differential diagnosis with treatment options including tofacitinib for confirmed cases.

Abbreviations

JDM	Juvenile dermatomyositis
MSA	Myositis specific antibodies
PCP	Primary care provider
CK	Creatine kinase
GGT	Gamma-glutamyl transpeptidase

LDH Lactate dehydrogenase

Acknowledgements

Not applicable.

Authors' contributions

MK carried out the patient's treatment plan in the inpatient setting and wrote the manuscript. SH contributed to the literature review, manuscript drafting, and revision, and approved the final manuscript as submitted. AK read the patient's initial pathology slides and provided a review of the sample before publication. VS, EF, and MI planned the patient's treatment in the inpatient setting, critically revised the manuscript, and approved the manuscript as submitted. MI supervised all aspects of the study and planned and carried out the patient's treatment plan in the outpatient setting before and after inpatient admission.

Funding

None.

Availability of data and materials

Data sharing does not apply to this article as no datasets were generated or analyzed during the current study.

Declarations

Ethics approval and consent to participate

See below.

Consent for publication

Written informed consent for publication of their clinical details and/or clinical images was obtained from the parent of the patient. A copy of the consent form is available for review by the Editor of this journal.

Competing interests

The authors declare that they have no competing interests.

Author details

¹Children's Mercy Hospital, Kansas City, MO, USA. ²School of Medicine, University of Missouri-Kansas City, Kansas City, MO, USA. ³Division of Pathology and Laboratory Medicine, Children's Mercy Hospital, Kansas City, MO, USA. ⁴Division of Gastroenterology, Hepatology, and Nutrition, Children's Mercy Hospital, Kansas City, MO, USA. ⁵Division of Rheumatology, Children's Mercy Hospital, Kansas City, MO, USA.

Received: 28 June 2024 Accepted: 29 August 2024

Published online: 17 September 2024

References

- Gara S, Jamil RT, Muse ME, et al. Juvenile Dermatomyositis. [Updated 2023 Jan 16]. In: StatPearls. Treasure Island (FL): StatPearls Publishing; 2024 Jan-. Available from: <https://www.ncbi.nlm.nih.gov/books/NBK534236/>
- Perron MM, Vasquez-Canizares N, Tarshish G, Wahezi DM. Myositis autoantibodies in a racially diverse population of children with idiopathic inflammatory myopathies. *Pediatr Rheumatol Online J*. 2021 Jun 12;19(1):92. <https://doi.org/10.1186/s12969-021-00574-6>.
- Zhang J, Xue Y, Liu X, Kuang W, Tan X, Li C, et al. Identification of 4 subgroups in juvenile dermatomyositis by principal component analysis-based cluster analysis. *Clin Exp Rheumatol*. 2022 Feb;40(2):443–9. <https://doi.org/10.55563/clinexprheumatol/t2hxjd>.
- Tansley SL, Betteridge ZE, Gunawardena H, Jacques TS, Owens CM, Pilkington C, et al. Anti-MDA5 autoantibodies in juvenile dermatomyositis identify a distinct clinical phenotype: a prospective cohort study. *Arthritis Res Ther*. 2014 Jul 2;16(4):R138. <https://doi.org/10.1186/ar4600>.
- Kobayashi I, Okura Y, Yamada M, Kawamura N, Kuwana M, Ariga T. Anti-melanoma differentiation-associated gene 5 antibody is a diagnostic and predictive marker for interstitial lung diseases associated with juvenile dermatomyositis. *J Pediatr*. 2011 Apr;158(4):675–7. <https://doi.org/10.1016/j.jpeds.2010.11.033>.
- Tosun A, Serdaroğlu G, Aslan MT, Polat M, Akalin T, Tekgul H, et al. Severe juvenile dermatomyositis: two patients complicated with extra musculo-cutaneous involvement. *Rheumatol Int*. 2006 May 24;26(11):1040–3.
- Nagashima T, Kamata Y, Iwamoto M, Okazaki H, Fukushima N, Minota S. Liver dysfunction in anti-melanoma differentiation-associated gene 5 antibody-positive patients with dermatomyositis. *Rheumatol Int*. 2019 May;39(5):901–9. <https://doi.org/10.1007/s00296-019-04255-2>.
- Patwardhan A, Rennebohm R, Dvorchik I, Spencer CH. Is juvenile dermatomyositis a different disease in children up to three years of age at onset than in children above three years at onset? A retrospective review of 23 years of a single center's experience. *Pediatr Rheumatol Online J*. 2012 Sep 20;10(1):34. <https://doi.org/10.1186/1546-0096-10-34>.
- Dunga SK, Kavachanda C, Gupta L, Naveen R, Agarwal V, Negi VS. Disease characteristics and clinical outcomes of adults and children with anti-MDA-5 antibody-associated myositis: a prospective observational bicentric study. *Rheumatol Int*. 2022 Jul;42(7):1155–65. <https://doi.org/10.1007/s00296-021-04897-1>.
- Shimizu M, Inoue N, Takeda Y, Kidouchi K, Fujita N, Fujiki T, et al. Concurrent Treatment With Rituximab and Plasma Exchange for Rapidly Progressive Interstitial Lung Disease Complicating Anti-MDA5 Antibody-Positive Juvenile Dermatomyositis. *J Clin Rheumatol*. 2021 Dec 1;27(8S):S798–9. <https://doi.org/10.1097/RHU.0000000000001460>.
- Sabbagh S, Almeida de Jesus A, Hwang S, Kuehn HS, Kim H, Jung L, et al. Treatment of anti-MDA5 autoantibody-positive juvenile dermatomyositis using tofacitinib. *Brain*. 2019 Nov 1;142(11):e59. <https://doi.org/10.1093/brain/awz293>
- Holzer MT, Krusche M, Ruffer N, Haberstock H, Stephan M, Huber TB, et al. New-onset dermatomyositis following SARS-CoV-2 infection and vaccination: a case-based review. *Rheumatol Int*. 2022 Dec;42(12):2267–76. <https://doi.org/10.1007/s00296-022-05176-3>.
- Altman A, Szyper-Kravitz M, Shoenfeld Y. HBV vaccine and dermatomyositis: is there an association. *Rheumatol Int*. 2008 Apr;28(6):609–12. <https://doi.org/10.1007/s00296-007-0485-4>.

Publisher's Note

Springer Nature remains neutral with regard to jurisdictional claims in published maps and institutional affiliations.